




SCIENTIFIC ANNALS of the School of Geology,
Aristotle University of Thessaloniki



SPECIAL VOLUME 102



ABSTRACT BOOK

Editors:

Dimitris S. KOSTOPOULOS, Evangelos VLACHOS, and Evangelia TSOUKALA

THESSALONIKI, MAY 2014

ARISTOTLE UNIVERSITY OF THESSALONIKI
FACULTY OF SCIENCES

ΑΡΙΣΤΟΤΕΛΕΙΟ ΠΑΝΕΠΙΣΤΗΜΙΟ ΘΕΣΣΑΛΟΝΙΚΗΣ
ΣΧΟΛΗ ΘΕΤΙΚΩΝ ΕΠΙΣΤΗΜΩΝ

SCIENTIFIC ANNALS OF THE SCHOOL OF GEOLOGY
SPECIAL VOLUME **102**

ΕΠΙΣΤΗΜΟΝΙΚΗ ΕΠΕΤΗΡΙΔΑ ΤΟΥ ΤΜΗΜΑΤΟΣ ΓΕΩΛΟΓΙΑΣ
ΕΙΔΙΚΟΣ ΤΟΜΟΣ **102**

ABSTRACT BOOK

OF THE VITH INTERNATIONAL CONFERENCE
ON MAMMOTHS AND THEIR RELATIVES

5-12 MAY 2014, GREVENA - SIATISTA

ΤΟΜΟΣ ΤΩΝ ΠΕΡΙΛΗΨΕΩΝ

ΤΟΥ 6^{ΟΥ} ΔΙΕΘΝΟΥΣ ΣΥΝΕΔΡΙΟΥ
ΓΙΑ ΤΑ ΜΑΜΟΥΘ ΚΑΙ ΤΟΥΣ ΣΥΓΓΕΝΕΙΣ ΤΟΥΣ

5-12 ΜΑΪΟΥ 2014, ΓΡΕΒΕΝΑ - ΣΙΑΤΙΣΤΑ

THESSALONIKI
ΘΕΣΣΑΛΟΝΙΚΗ
2014

Histological evaluation of tissue structure preservation in the Malolyakhovski mammoth

Darima GARMAEVA ✉, Mariia BUZINAEVA, Grigoriy SAVVINOV, Semyon GRIGORIEV,
Sergei FEDOROV, Alexei TIKHONOV, Gavril NOVGORODOV, and Maksim CHEPRASOV

Success in the comprehensive research on mammoth and accompanying fauna largely depends on the degree of preservation of soft tissue in cadavers of these ancient animals, which are unique finds of great value to science.

In order to determine the state of cellular and tissue structures, we conducted a histomorphological study of fragments of a carcass of an adult female mammoth found on the Malyi Lyakhovsky Island (New Siberian archipelago) in August, 2012.

Results of the first histological studies of the tissues of the Malolyakhovski mammoth trunk demonstrated varying degrees of preservation of tissues. Histological sections obtained in the imaging of tissue fragments show striated muscles, dense unformed connective tissue, and fragments of adipose tissue in the form of large clusters of fat cells (white adipocytes) with an optically empty cytoplasm, surrounded by a rough thin shell (Fig. 1).

Blood vessels of muscle type were found on the histological slices of tissue samples from the distal part of the mammoth's trunk. In this case, the vessel lumen is filled with a homogeneous mass of yellowish-pink color, probably a well-preserved clot of hemolyzed blood (Fig. 2). Under a light microscope it is possible to distinguish the rough form blood cells membrane. Moreover, in the walls of small blood vessels blue-violet nuclear elements were revealed of unevenly shaped undifferentiated cells, probably endothelial cells.

Thus, the results of the first histological researches of the tissue fragment of the Malolyakhovski mammoth trunk show the relative preservation of cellular and tissue structures. For the first time, histological samples of the mammoth trunk revealed soft tissues, a blood vessel of muscle type with a homogeneous mass, more like the

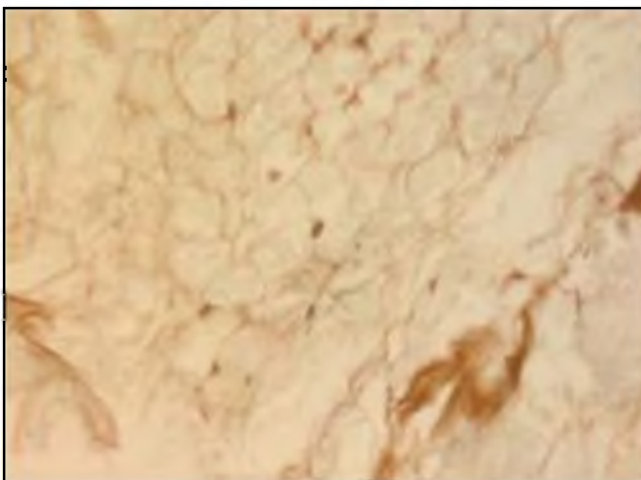


Fig. 1. Fragments of adipose tissue in the form of clusters of irregular shapes of white fat cells with clear cytoplasm in the soft tissues of the mammoth trunk (Inverted microscope Carl Zeiss, Axio. X 400).

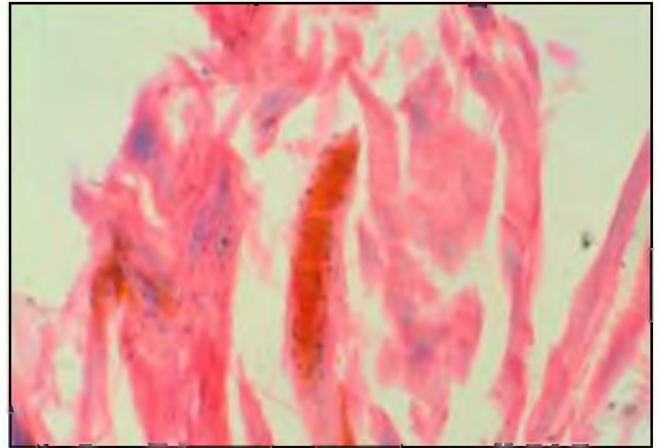


Fig. 2. Soft tissue of the distal part of the adult female mammoth's trunk. In the center of the blood vessel is a muscle-type small-caliber lumen, filled with hemolyzed blood. Hematoxylin and eosin. X 200.

hemolyzed blood clot. In earlier reports from studies of mammoth soft tissues only histologically differentiated and empty vessel lumens were described, which is typical for tissues exposed to severe mummification. Further histological studies of the soft tissue and internal organs of the Malolyakhovski mammoth will continue after the remains of the carcass are delivered to Yakutsk.

References

- Argunov, V.A., Nikoforov, O.I., Chernyavsky, V.F., 2007. Histomorphology of Yukagir mammoth tissues. Yukagir mammoth. G.G. Boeskorov, A.N. Tikhonov, N. Sudzuki. Saint Petersburg: Publishing House St. Peterborough University, 252 p.
- Lazarev, P.A., Boeskorov, G.G., 2010. The results of Mammoth and Mammoth Fauna study in Yakutia. Papers of the IV International Mammoth Conference. Yakutsk, pp.10-17.
- Michelson, V.M., Kudryavcev, B.N., Chernogradskaya, N.A., Sabinin, G.V., Pleskach, N.M., 1982. Cytological Safety of Khatanga Mammoth. Collection of papers «Mammoth Fauna of Asian part of the USSR». Leningrad, pp. 27-29.
- Repin, V.E., Pugachev, V.G., Taranov, O.S., Ryabchikova, E.I., Alexeev, A.Y., Lazarev, P.A., Boeskorov, G.G., Savvinov, D.D., Savvinov, G.N., Protopopov, A.V., 2003. Preliminary Results of Maksynokhsy Mammoth Expedition 2002. Collection of papers International Conference «Applied Ecology of the North: experience of conducted research, modern state and perspectives». Yakutsk, pp. 275-283.
- Taranov, O.S., Totmenina, O.D., Pugachev, V.G., Ryabchikova, E.I., Chernyavsky, V.F., Tikhonov, A.A., Repin V.I., 2004. Microbiological and Histological Researches of Yukagir Mammoth Head. Thesis of International Scientific Conference «Yukagir Mammoth: The First Stage Results». Yakutsk, 24 p.
- Yudichev, Y.F., Averikhin, A.I., 1982. Of Macro and Micro Morphology of Shadrinsky Mammoth Abdomen Organs and The Reasons of its Death. Collection of papers «Mammoth Fauna of Asian part of the USSR». Leningrad, pp. 27-29.

✉ dari66@mail.ru



Citation:

Garmaeva, D., Buzinaeva, M., Savvinov, G., Grigoriev, S., Fedorov, S., Tikhonov, A., Novgorodov, G., Cheprasov, M., 2014. Histological evaluation of tissue structure preservation in the Malolyakhovski mammoth. Abstract Book of the VIth International Conference on Mammoths and their Relatives. S.A.S.G., Special Volume 102: 63.